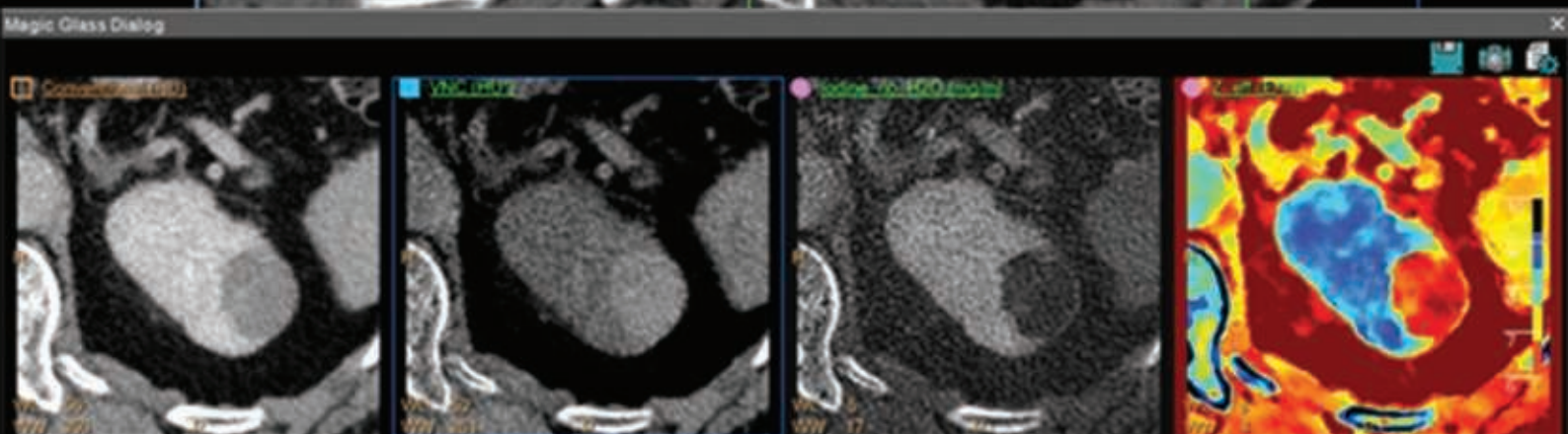
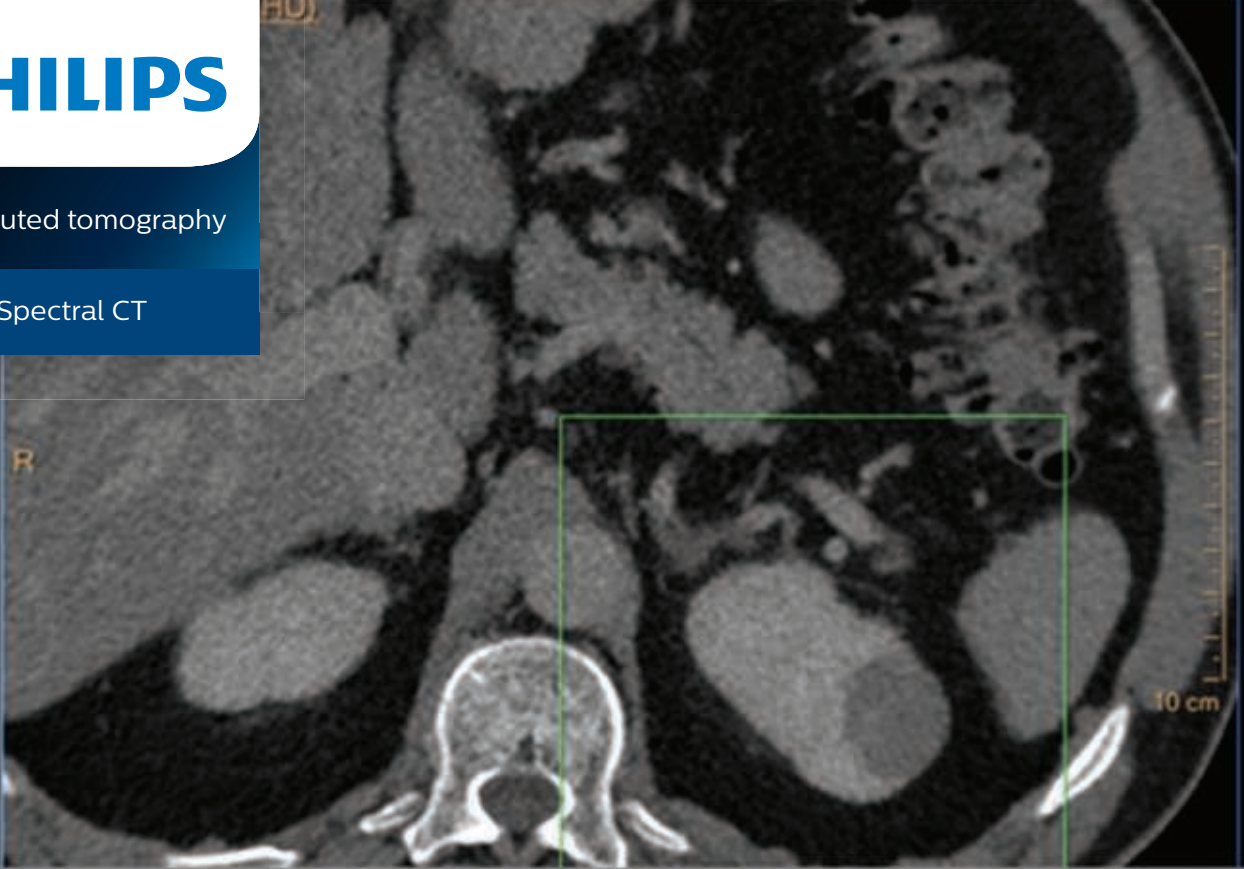


PHILIPS

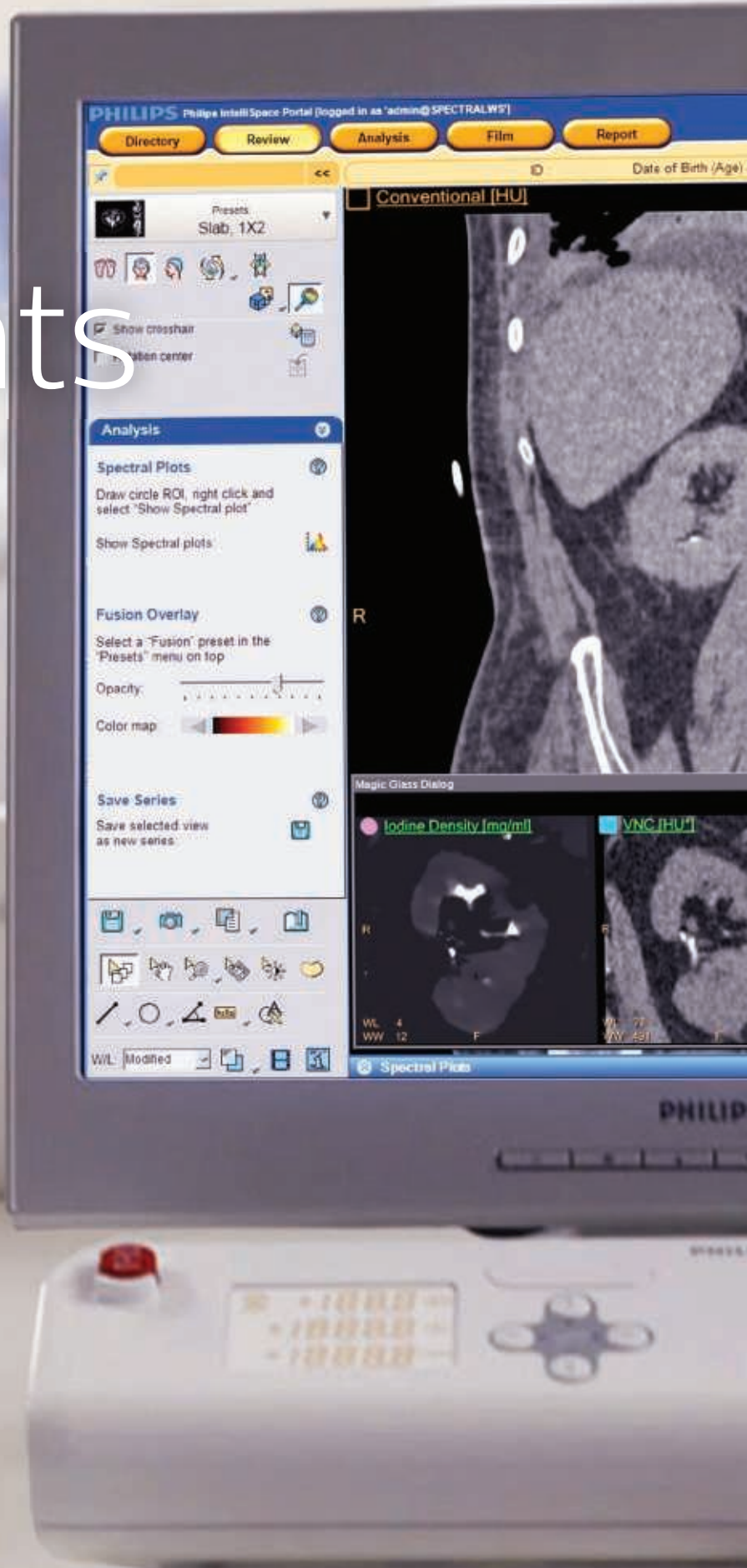Computed tomography

IQon Spectral CT



A scientific review of dual-energy and spectral computed tomography imaging

Contents



Introduction	4
The role of anatomical and tissue compositional information in disease diagnosis	6
Improve diagnostic confidence	6
Reduce follow-up studies	7
Reduce repeat imaging scans	7
Spectral CT Imaging	8
The physics behind spectral CT detection	8
Approaches to spectral image generation	9
Detector technology	12
The Philips NanoPanel Prism detector design	12
The scintillators and front-illuminated photodiode	12
Front-end electronics	13
Benefits derived from the NanoPanel Prism detector design	14
Obtaining spectral results with the IQon Spectral CT	15
Spectral reconstruction on the IQon Spectral CT	15
The Spectral Base Image	19
Spectral results available on the IQon Spectral CT	20
Dose management tools available on the IQon Spectral CT	21
Retrospective analysis and enhanced spectral visualization on the IQon Spectral CT	22
Clinical experience with IQon Spectral CT	24
Increased diagnostic confidence thru improved tissue visualization and characterization	24
High quality spectral images with no dose penalties	26
High quality spectral results from a single scan	28
Powerful advancements—decrease artifacts and enhance image quality	30
Diagnostic certainty through multiple layers of spectral data, the first exam is the right exam	32
Diagnostic confidence at low contrast dose levels	34
Spectral results 100% of the time, eliminating the patient selection dilemma	35
Improve patient care and realize long-term economic benefits	36
Summary	38
Works cited	40



Introduction

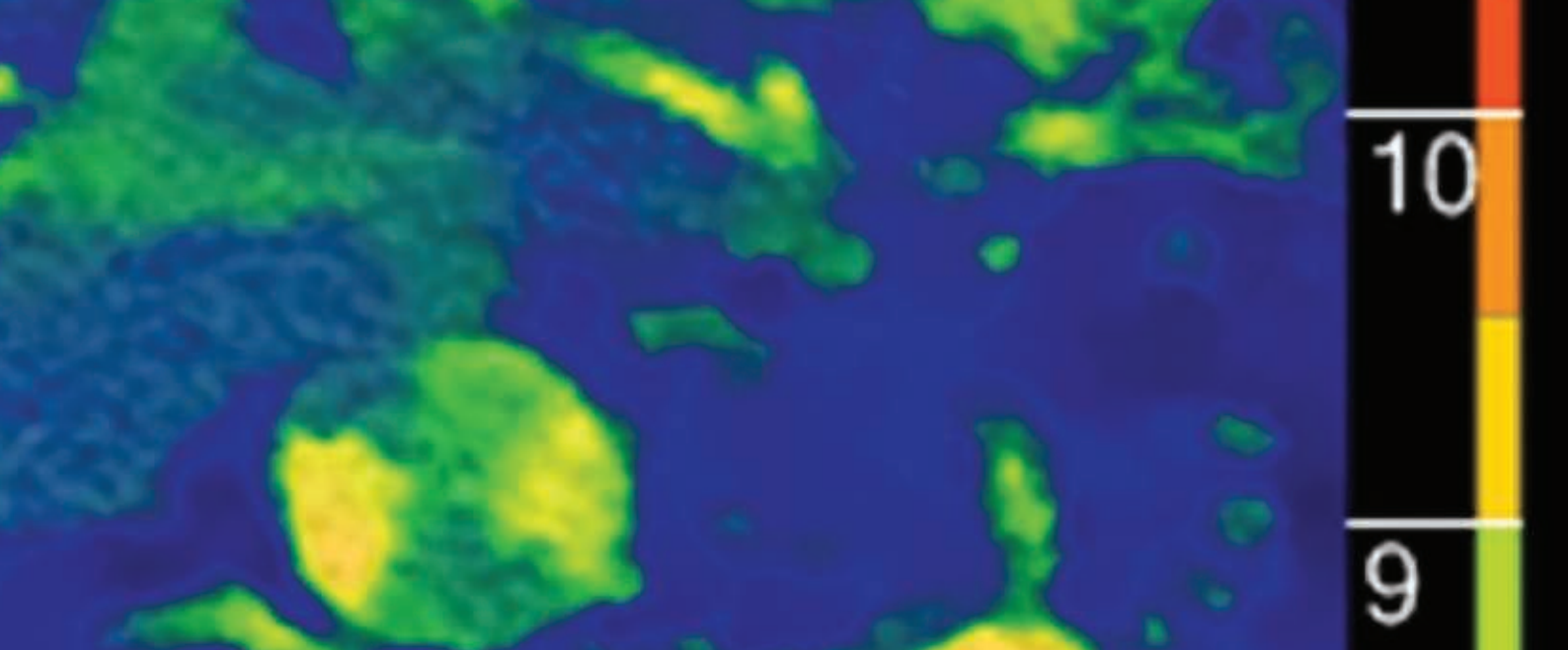
Dual-energy computed tomography (CT), sometimes referred to as spectral CT, is an imaging technology that allows clinicians to differentiate the various elements in the body based on their material density and atomic number, providing both anatomical and tissue composition information. Since its inception, dual-energy CT imaging has proven useful in boosting clinical diagnostic confidence when compared to conventional CT scans.

Studies at university hospitals and centers of excellence have demonstrated the clinical and patient benefits of utilizing spectral technology across a range of clinical indications, including cardiac, neurological, musculoskeletal, genitourinary, vascular and oncology. However, the potential of dual-energy CT scanners in mainstream clinical settings has yet to be realized.

Most frequently cited challenges of spectral imaging:

- Changes in routine clinical workflow
- Potentially higher than normal dose exposure to patients
- Reduction in conventional CT image quality for radiologist to diagnose from

The majority of dual-energy imaging systems available in the market today are source-based systems, i.e. they provide the dual energy through X-ray source/s to generate the data required for a spectral CT image. While source-based approaches generate the various data sets required for a spectral image, they require clinicians to prospectively determine the need for a spectral scan. Dose modulation tools that are typically available on conventional CT scanners are limited in source-based spectral modes, and conventional CT image quality suffers from increased noise generated by these approaches.



A significant advancement in spectral imaging from a source-based approach was realized with the introduction of the Philips IQon Spectral CT, a dual-layer, detector-based approach: i.e. the energy required to create a spectral image is separated by the detector, rather than the source.

Benefits experienced with a detector-based approach to spectral imaging:

- Clinicians may choose to retrospectively view spectral data
- Dose modulation tools are always available
- Conventional image quality is not impacted with detector-based spectral data collection

Detector-based spectral CT imaging boosts diagnostic certainty and reduces the number of follow-up exams required for several clinical applications. Using monoenergetic spectral results, clinicians can reduce beam hardening artifacts and metal implant artifacts. Spectral-derived iodine maps, non-contrast images and monochromatic energy attenuation images improve identification of vascular structures and underlying tissue composition, aiding in reducing contrast dose requirements. By basing diagnoses on both anatomical structures as well as tissue characteristics, clinicians are able to more conclusively detect and characterize tumors, assess the hemodynamic significance of pulmonary embolisms, and characterize renal calculi, amongst several other uses.

This monograph presents evidence to demonstrate and support why detector-based spectral imaging should be the method of choice in routine clinical practice in hospitals and CT imaging centers. It reviews the role of spectral CT imaging in clinical diagnosis, the physics behind spectral imaging, the various techniques used to generate spectral data, and presents clinical efficacy and usefulness of a detector-based approach to spectral imaging. Several studies demonstrate how detector-based spectral imaging, exclusive to the Philips IQon Spectral CT, improved diagnostic confidence for clinicians and helped them overcome workflow challenges presented by source-based spectral imaging techniques, with no loss in functionality of dose modulation tools or conventional image quality.

The role of anatomical and tissue compositional information in disease diagnosis

The pathology of diseased tissues is characteristically different from healthy and alternate disease states. For example, an aggressive hepatic sarcoma contains a vascular bed that would not be present within a hepatic cyst. Patient prognosis and managing patient care varies greatly across these two conditions. Material composition can also vary across similarly presenting conditions. For example, both uric acid and calcium oxalate nephrolithiasis present similarly, but treatment regimens vary drastically because of occluding stone compositions. Often times, in challenging imaging cases, such as with metal implants or bone structures, radiologists find it difficult to view the surrounding tissues. Conventional CT scans do not always provide clinicians with sufficient information to make the confident diagnosis needed to begin treatment. With conventional CT scans, the aforementioned disease states would require follow-up scans using alternative modalities or biopsies that would significantly degrade the patient experience by making them vulnerable to additional testing and delayed results, and exposing the institution to more costs.

Spectral data helps clinicians to:

- Improve diagnostic confidence
- Reduce follow-up studies
- Reduce repeat imaging scans

Improve diagnostic confidence

The importance of confidence in imaging diagnostic tests cannot be overstated. With today's value-based reimbursement structures and demand for improved clinical outcomes, confident diagnosis is increasingly becoming a necessity. Each step of the diagnostic process should provide quality and actionable results. If image quality is poor or potential pathology is not clearly visible due to scanning technology limitation, clinicians can find it difficult to begin proper treatment regimens. Patients have the best opportunity for a positive health outcome when clinical decisions are personalized to a patient's health problem and based on diagnosis that is accurate and made in a timely manner.^{1,2} Imaging technology, CT in particular, plays a major role in boosting diagnostic confidence in primary care and emergency departments.^{3,4} The more useful information around the disease state an image can provide, the greater the confidence the clinician will experience in making a diagnosis and starting treatment. The probability with which a disease state needs to be diagnosed, in order for treatment to be justified, does not need to be absolute.⁵ The image used for diagnosis at minimum must support a degree of certainty about the diagnosis, an understanding of the harms and benefit of treatment, and some insight to the harms

and benefit of further information-gathering activities, including the impact of delaying treatment.

Reduce follow-up studies

The risks associated with diagnostic testing are an important consideration for clinicians conducting information gathering activities in the diagnostic process. While underuse of diagnostic testing leads to treatment decisions being made with incomplete information, which has been a long standing concern in the field⁶, overly aggressive diagnostic strategies can put patients at greater risk for harm, and they do not necessarily improve the diagnostic accuracy or certainty for a patient.^{5,7} CT technology provides clinicians with a low risk and high information opportunity that is often leveraged to face the ever-increasing demand to make clinical decisions quickly and accurately.³ However, when conventional CT images show the presence of singular lesions or tumors, additional information beyond anatomical structures is required and often followed by invasive surgical biopsies. Clinicians must consider not only the diagnosis, but also the cascade of diagnostic testing and treatment decisions that could stem from a diagnostic test result. The costs associated with follow-up testing represent the opportunity cost in time, money and patient comfort. Narrowing the diagnosis with the first test will ensure fewer follow up tests before the onset of treatment, and ultimately improve patient care.^{5,7}

Reduce repeat imaging scans

Even non-invasive tests to determine anatomical or tissue compositional information can pose potential harm. Although the risk from a diagnostic imaging examination is small, it is not zero. Especially when the underlying imaging technology is powered by radiation or a contrast agent is required to be consumed by the patient. Hence, it is always best to limit the number of imaging exams for a particular patient to as few as possible. While unclear scans or insufficient scans, such as those due to missed timing with contrast agents, will happen, it is pertinent to remember that there are costs beyond money and time that are associated with repeating scans.

A potential area for improvement in diagnostic imaging is multiphase examinations. Multiphase examinations are comprised of studies that repeat examinations over the same anatomic area and are performed relative to the administration of intravenous contrast material. Pre-contrast studies are the most familiar, but early- (arterial), mid- (venous), and late- (delay) phase CT scans may also be performed.⁸ Every additional scan adds radiation burden to the patient and can compromise their health and/or recovery.⁸ As a general rule of thumb, the amount of radiation used should always be kept as low as reasonably achievable (ALARA).⁹ Good practice requires the use of patient-specific protocols and techniques to minimize dose without adversely impacting the diagnostic efficacy of images.^{9,10,11}

Spectral CT imaging

The physics behind spectral CT detection

CT uses X-rays to generate cross-sectional, two-dimensional images of the body. CT images are acquired by the rapid rotation of an X-ray tube 360° around a patient. A polyenergetic X-ray tube spectrum, at a set peak energy, is targeted at the patient. The average attenuated radiation is then measured by a ring of sensitive radiation detectors present on the gantry behind the patient. The final image is generated from these measurements, utilizing the basic principle that the distribution of a material in an object layer can be calculated if the integral values along any number of lines passing through the same layer are known.¹²

With conventional CT scans, each pixel is assigned a numerical value (CT number), which is the average of all the attenuation values contained within the corresponding voxel. This number is compared to the attenuation value of water and displayed on a scale of arbitrary units named Hounsfield units (HU) after Sir Godfrey Hounsfield, the inventor of CT. As a result, many different tissues with similar densities may have overlapping HU values at a given peak tube voltage (kVp).

The two main mechanisms contributing to CT attenuation coefficients of materials are the photo-electric effect and Compton scattering, which are both energy- and material-dependent.

The photoelectric effect predominates at lower photon energies and is heavily energy-dependent, while Compton scattering occurs at energies exceeding 50 keV. The photoelectric effect is related to high atomic numbers, whereas the Compton effect is predominantly related to the electron density of the material. Spectral CT measures the difference in attenuation of X-rays at two energy levels, high and low. Data collected simultaneously from two energy levels can be used to determine the Compton scatter and photoelectric components of x-ray attenuation. These components, taken

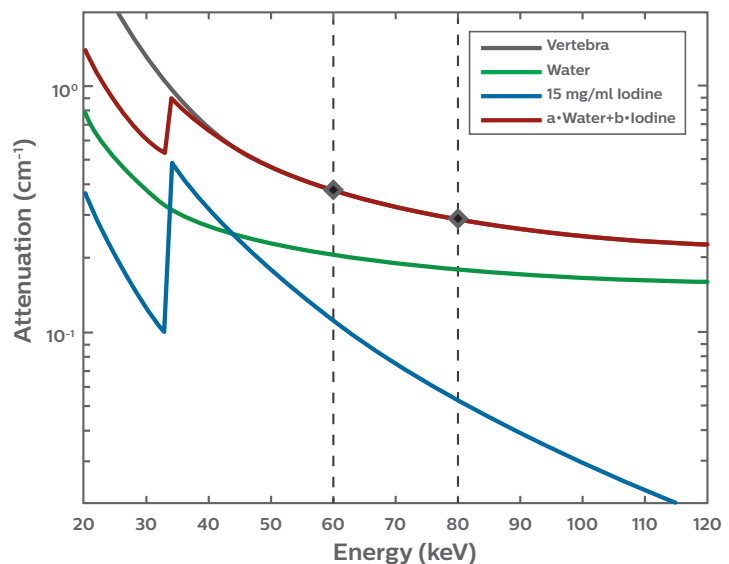


Fig. 1 Attenuation curves and K-edge depicted for various materials. Using the unique curve characteristics for different materials, both density and atomic number of material can be identified.

together, provide additional information about tissue density and atomic number that can be exploited to separate tissues with similar attenuation in a conventional image.¹³

In addition to measuring and leveraging the attenuation of X-rays at different energy levels, spectral CT can leverage the binding energy of the K (outermost) shell electron of an atom. Demonstrated in Fig. 1, there is a spike in the attenuation coefficient of photons, as a result of the photoelectric absorption, occurring at photon energies at or just above the binding energy of the K shell electron of the atom interacting with the photons. An activation energy, greater than the binding energy of the K shell electrons (K-edge), is necessary for this interaction to occur. A photon having an energy just above the binding energy of the electron is more likely to be absorbed than a photon having an energy just below this binding energy.¹⁴

K-edge imaging is an important application of spectral CT imaging. Iodine and barium are two radiopharmaceuticals with ideal K shell binding energies, near the mean energy of most diagnostic x-ray beams, at 33.2 keV and 37.4 keV, respectively.^{15,16,17} By resolving the detectability of attenuated x-ray energies into fine bins, the unique K-edge coefficient signatures of different materials can be leveraged to distinguish them. Additionally, this may open the door for spectral CT to support functional, cellular and molecular imaging studies.^{18,19,20,21}

Approaches to spectral image generation

Source-based imaging

The two primary modes to generating spectral images are source-based and detector-based. Source-based approaches include using multiple sources, or using a single source in a modulated fashion, to generate the energy levels needed to create a spectral scan. Source-based methods include dual-source, kVp-switching and dual-spin.

- Dual source CT uses two separate tubes integrated in the same scanner.
- kVp switching involves rapidly switching the kV tube potential to acquire data at two different tube voltages.
- Dual spin CT acquires two successive spiral scans at different kVp and mA levels from a single source.

Spectral CT imaging

Dual-source, kVp-switching, and dual-spin techniques require the clinician to pre-select patients for dual-energy scanning. Because the acquisition of spectral data is dependent on the X-ray tube, certain trade-offs have remained with regards to special modes, image quality, and dose penalties.

Limitations of source-based spectral imaging:

- Spectral imaging is not always available and has to be preselected prior to scan
- The field of view (FOV) can be compromised, with some approaches, limiting its use in larger patients
- Scan speeds are required to be reduced depending on approach, impacting temporal resolution
- Full suite of standard dose modulation tools may not be available when performing dual-energy acquisitions with some approaches, exposing patients to higher doses than required

Detector-based spectral imaging

Unlike source-based spectral options, detector-based approaches simultaneously absorb high and low energy, available in a polyenergetic X-ray beam, at the detector level. Prospective and retrospective spectral results are acquired within a single scan without the need for special modes. Because the separation of spectral data occurs at the detector rather than the X-ray tube, there is no need to decide in advance whether to use a spectral protocol.

Advantages of detector-based spectral imaging:

- The clinician can adhere to the familiar conventional workflow, while retaining the full use of dose management tools with no compromise in the imaging field of view
- The patient is scanned as usual and a conventional anatomical image along with spectral information can be generated and interpreted in a single scan
- Should the clinician decide that spectral information would be of additional value in a particular region of interest, the spectral information acquired during the single scan can be easily accessed for retrospective, on-demand spectral data analysis
- Standard dose modulation tools are not impacted

	Dual-Source	kVp-Switch	Dual-Spin	Detector-based Spectral
How it works	<ul style="list-style-type: none"> • Special spectral mode • Must be preselected • 2 tubes • 80 or 100/140 kVp 	<ul style="list-style-type: none"> • Special spectral mode • Must be preselected • Fast kV switching • 80/140 kVp 	<ul style="list-style-type: none"> • Special spectral mode • Must be preselected • 1st spin at 80 kVp • 2nd spin at 140 kVp 	<ul style="list-style-type: none"> • No special spectral mode required • Spectral is always on • Scan at 120 kVp • Tube mA modulation • Dose neutral
Results Generation	Prospective	Prospective	Prospective	Retrospective and Prospective
Acquisition Mode	Dual-energy	Dual-energy	Dual-energy	Conventional
Consistent Datasets	Quarter rotation offset	Nearly perfect alignment	Very large offset	Perfect alignment
Reconstruction	Image space	Projection space	Image space	Projection space
120 kVp Conventional Image	No	No	No	Yes
Dose Modulation Available	Yes	No	Yes	Yes
FOV	Limited	Full	Full	Full

Table 1 A comparison of detector-based and source-based spectral approaches

Detector technology

Material decomposition through energy-selective CT was proposed as early as 1976 by Alvarez and Macovski. The earliest approaches to achieve material decomposition were source-based. A Philips team proposed a different configuration and implementation of that idea through two attached scintillator layers, optically separated, and read by a side-looking, edge-on, silicon photodiode, thin enough to maintain the same detector pitch and geometrical efficiency as a conventional CT detector (Fig. 2). This dual-layer spectral detector system configuration leverages the polyenergetic nature of an X-ray beam and enables always-on spectral detection.

The Philips NanoPanel Prism detector design

The NanoPanel Prism detector allows for simultaneous measurements of both high and low energies in the same time and space. The detector consists of a 3D tile-patterned arrangement in which each module contains three highly integrated components – scintillators, thin front-illuminated photodiode (FIP), and application-specific integrated circuit (ASIC).

The scintillators and front-illuminated photodiode

The scintillators convert X-rays to visible light, and the FIP converts this light into an electrical signal. In the NanoPanel Prism detector, the design of the two scintillators' thickness is optimized for energy separation and optimal signal-to-noise ratio (SNR), as shown in Fig. 3. The yttrium-based garnet scintillator effectively absorbs low-energy x-rays while the GOS absorbs as much as 99% of the energy spectrum.




Fig. 2 Philips NanoPanel Prism detector design schematic

The optimized performance and geometrical parameters of the scintillators, together with the FIP usage, allow 25% higher light output and 30% less cross talk than previous detectors, maintaining high enough signal statistics for the low-energy raw data, even for a large patient.

The fully simultaneous acquisition of the two energy spectra by the dual-layer detector leads to a more accurate determination of material concentrations (such as iodine and barium). In addition, the dual-layer detector method does not suffer from some of the practical constraints on high-enough dose delivery of 80 kVp at fast scanning modes in dual energy mode that are characteristic of modern multi-detector CT. Furthermore, at 120 kVp, the dual-layer configuration still enables iodine quantification from soft tissues with a SNR lower than that obtained at 140 kVp by only 18%. The latter observation, together with the dual-energy acquisition characteristic, independent of the CT scan protocol and field of view, enables the use of the system as a spectral-energy CT in a retrospective mode after the scan, upon users' request and need.

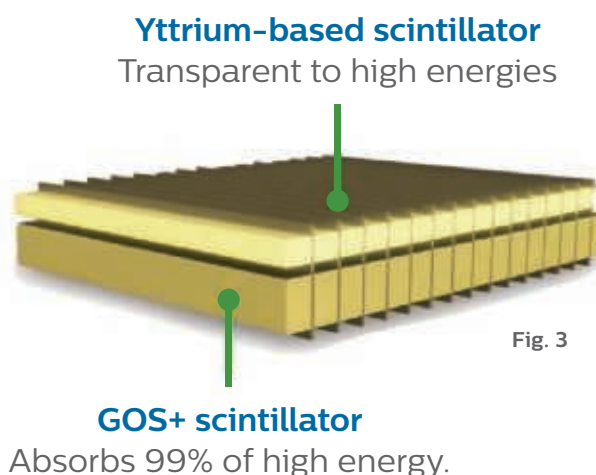


Fig. 3

Front-end electronics

The application-specific integrated circuit (ASIC) is used in a unique manner, such that it allows for analog-to-digital conversion of signals with very low power dissipation and still maintains low noise (both wideband and low frequency noise). The ASIC is mounted closely to the FIP for better layout, shorter lines, and better analog to digital isolation to minimize electronic noise and decrease signal drift. The low electronic noise leads to improvements in the SNR with negligible interlayer scatter, resulting in high image quality at low dose.

Detector technology

Benefits derived from the NanoPanel Prism detector design

- The NanoPanel Prism detector demonstrates excellent characteristics in consistency, dynamic range, stability, signal uniformity, linearity, low noise characteristics, low cross-talk values, and high geometric and quantum efficiencies, which allow the IQon Spectral CT to obtain excellent image quality.
- The detector system design, materials, and simultaneity of data sets provides a unique scanning and clinical application experience for the user. The spectral scanning routine has minimum decision points, which means that CT scanning protocols do not need to be altered. Predecisions on whether to perform spectral CT scans are not required because the scans are always spectral scans.
- The scanning workflow means CT protocols with clinical questions related to spectral results can be generated at the operating console, with the choice of performing retrospective spectral image generation. Dedicated clinical applications can use the new data, allowing for clinical information interrogation and excellent image quality.

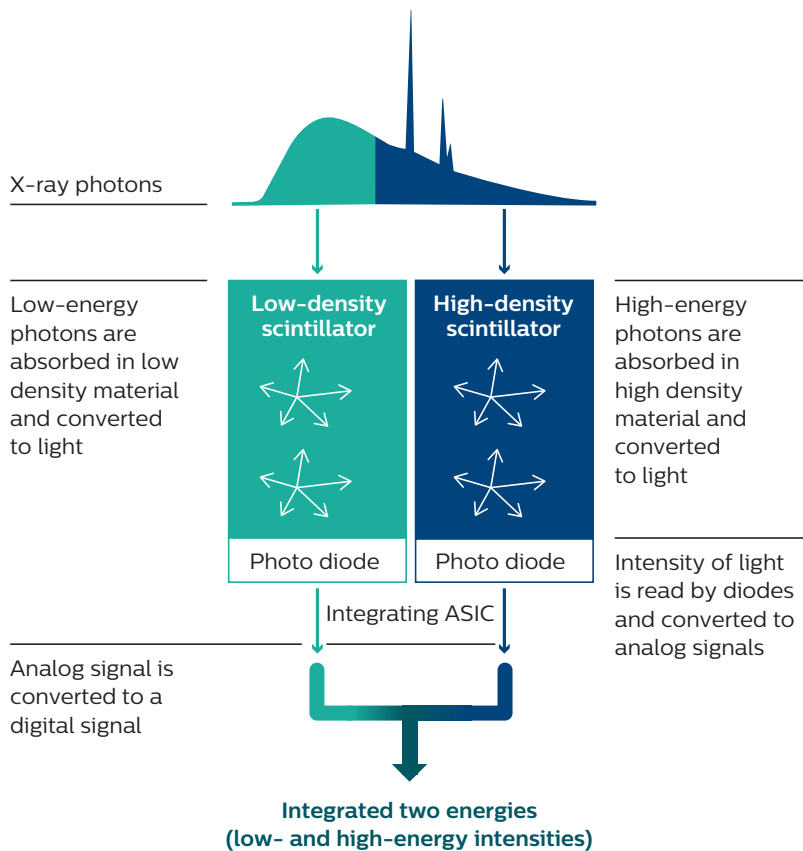


Fig. 4 The unique dual layer scintillator system allows high- and low-energy data to be obtained simultaneously.

Obtaining spectral results with the IQon Spectral CT

Spectral reconstruction on the IQon Spectral CT

Spectral separation is the first step in obtaining quality spectral results. The NanoPanel Prism detector is designed to create every advantage to obtain spectral data with the strongest signal-to-noise ratio. This input is then fed into a proprietary reconstruction algorithm on the IQon Spectral CT that enables the generation of various spectral results.

Detector-based spectral imaging has the advantage of simultaneously acquired (spatially and temporally) measurements of high- and low-energy projection datasets, across the two detector layers. This enables the leveraging of anti-correlated noise algorithms to suppress the noise in the image data sets, so anti-correlation is not lost in spatial or temporal extrapolations. Additionally, detector-based separation of spectral data sets allows the use of model-based iterative reconstruction techniques as the high- and low-energy projection datasets are used for conventional spectral reconstruction, leading to a further reduction in image noise.²²

In a recent study, Brown, et al. compared the performance of a realistic dual-layer spectral CT system (IQon Spectral CT) with an ideal detector having perfect energy separation.²² When combined with an appropriate reconstruction method, they showed that the performance of the realistic detector nearly matched the ideal detector for a given material classification task (Fig. 5). Furthermore, they showed that a proper statistical reconstruction approach could dramatically improve the impact of the energy spectral separation on the final image quality.

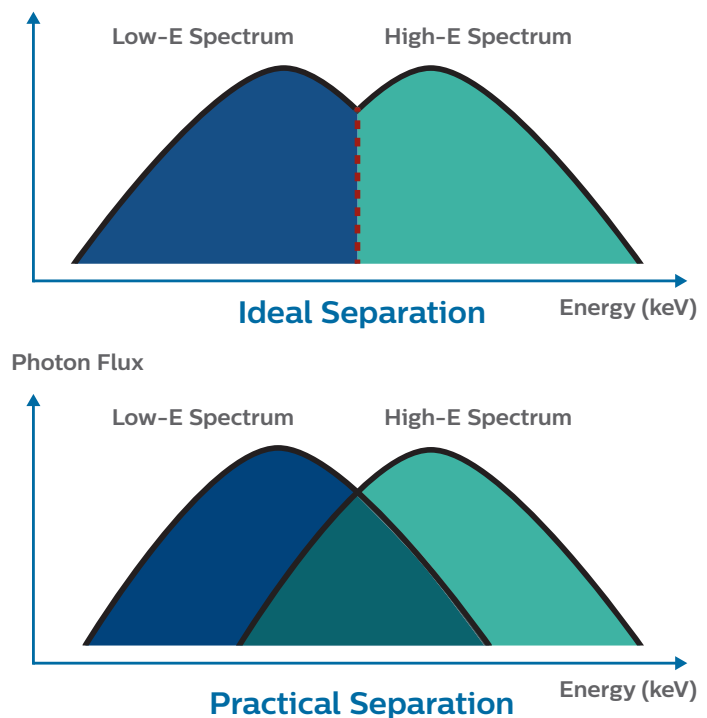


Fig. 5 The ideal separation has a perfect cutoff with no overlap between energies in the different layers. The practical spectral separation shows considerable overlap in the energies which deposit in the upper and lower layers.

Obtaining spectral results with the IQon Spectral CT

Full characterization of a dual-energy CT system must take into account the reconstruction algorithm, which can deliver dramatic improvements when utilizing the unique features of the noise in the basis decomposed images, especially the anti-correlated noise.

Brown, et al. also noted that this evaluation did not prove that energy separation is irrelevant in every situation. As non-linear algorithms are involved, a full comparison needed to be task-based, and the results might be quite different depending on the task. However, for the task of accurate material classification with the objects and tube currents used, the study found that a real dual-layer detector, coupled with a proper reconstruction algorithm, is quite competitive, even when compared to an ideal detector with perfect energy separation (Fig. 6).

The advantage of anti-correlated noise cancellation was further demonstrated in an independent study, conducted by Sellerer, et al.,²³ comparing the different spectral image generation approaches.




Fig. 6 Comparisons of reconstruction methods (Filtered Back Projection (FBP) and Spectral (AC-ROF) reconstruction demonstrates the importance of the reconstruction algorithm in final image quality. Reconstructions from both detectors using spectral algorithms are shown in the right-hand column. The strong impact of the anti-correlated reconstruction can easily be seen—now, the images from the different detectors are much more visually closer.

Fast kVp-switching and dual-source spectral imaging are not perfectly aligned in spatial and temporal resolution of high and low photon energy detection, as such are not positioned to leverage anti-correlated noise reduction approaches.

In the study performed by Sellerer, et al., a semi-anthropomorphic abdomen phantom was imaged using a detector-based CT (DBCT), a dual-source dual-energy system (DSCT), and a fast-kVp-switching dual-energy system (KVSCT). Scans were simulated for three patient sizes and for $CTDI_{vol}$ levels of 10 mGy, 20 mGy and 30 mGy. Noise and quantitative accuracy of phantom Hounsfield units (HU) and iodine concentration were evaluated for a range of resultant monoenergetic images. The results from the study demonstrated:

- A steep increase in image noise is observed for keV levels below 80 keV for fast-kVp-switching and dual-source approaches, while the change in noise is rather low in the case of detector-based approaches (Fig. 7).

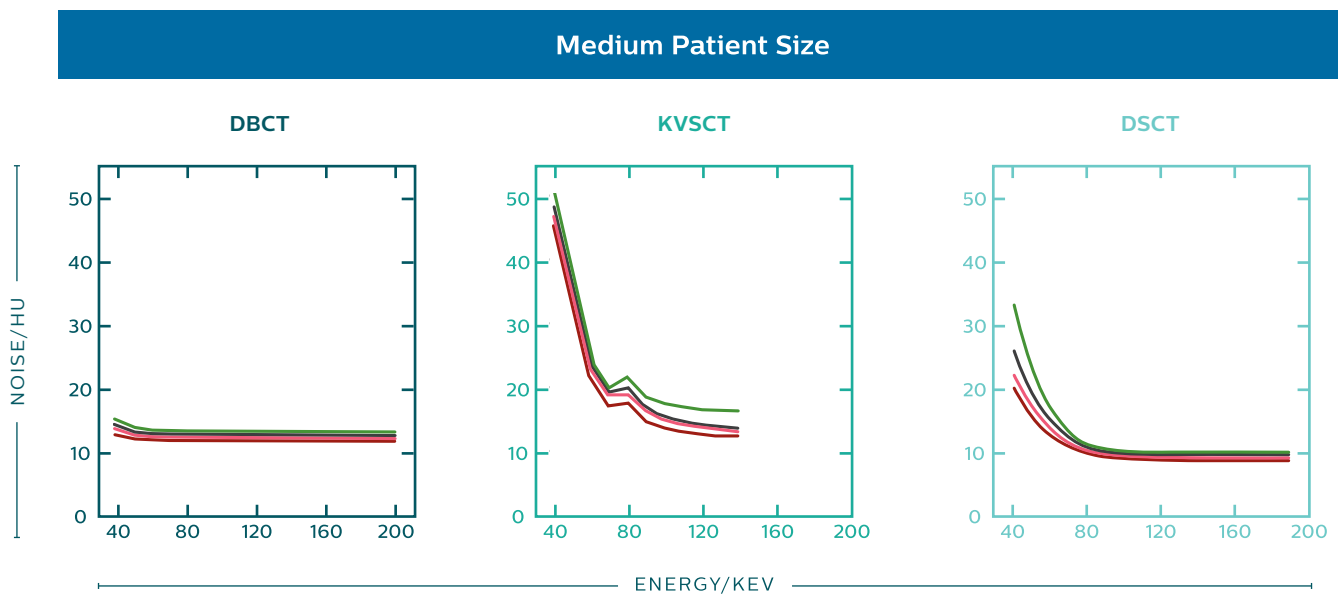


Fig. 7 Image noise over the available virtual monoenergetic images (VMI) energy ranges of detector-based CT, fast-kVp-switch CT and dual-source CT. Noise is given in units of HU (standard deviation) at 20 mGy $CTDI_{vol}$ and for each CT system

Obtaining spectral results with the IQon Spectral CT

- Virtual monoenergetic image quality was comparable for detector-based and dual source-based approaches for spectral imaging at mid to high energy levels, and image quality was significantly reduced for fast-kVp-switching approaches at lower monoenergetic levels (Fig. 8).

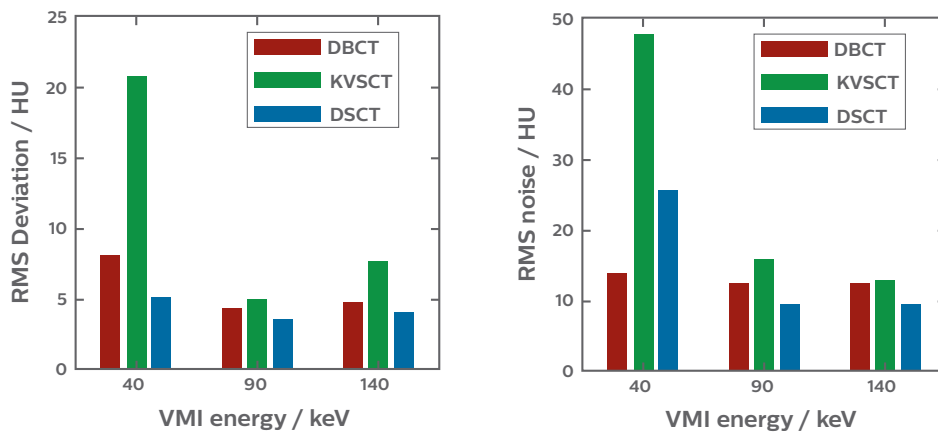


Fig. 8 Comparison of VMI quality obtained with detector-based, kVp-switching and dual-source CT at three energy levels. The plots show data for the medium patient size and 20 mGy $CTDI_{vol}$. The left plot shows the root mean square deviation (RMSD) observed from true HU values, whereas the right plot indicates the measured RMS noise. In both plots, RMS values have been calculated over all soft tissue-equivalent phantom inserts.

- Detector-based and fast-kVp-switching approaches deliver comparable absolute errors of measured iodine concentration. The mean errors in source-based spectral CT are notably larger (Fig. 9).

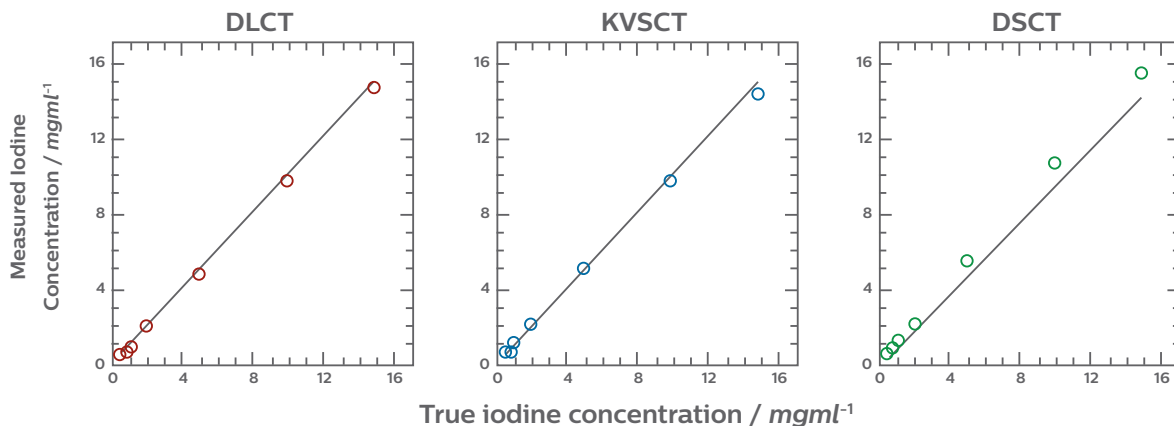


Fig. 9 Observed iodine concentrations and absolute errors for the medium sized phantom and 20 mGy $CTDI_{vol}$. Line-plots show high correlation between observed and true iodine concentrations for detector-based CT (DBCT), fast-kVp-switching CT (KVSCT) and dual-source CT (DSCT). The mean signed deviation between observed and true concentrations is analyzed by Bland-Altman plots.

- The root mean standard deviation (RMSD) of iodine concentrations was lowest for the detector-based approach in eight of the nine patient size/dose configurations tested, and comparable to the kVp-switching approach of spectral imaging in the ninth configuration (Table 2).

Patient Size	DBCT			KVSCT			DSCT		
	10 mGy	20 mGy	30 mGy	10 mGy	20 mGy	30 mGy	10 mGy	20 mGy	30 mGy
Small	0.07	0.07	0.03	0.17	0.24	0.31	0.70	0.72	0.71
Medium	0.20	0.17	0.14	0.31	0.30	0.31	0.79	0.77	0.77
Large	0.18	0.26	0.36	0.74	0.51	0.31	0.97	0.91	0.93

Table 2 RMSD of observed iodine concentrations (with respect to true values) for different measurement configurations and CT systems. Deviations are given in mg/ml

The Spectral Base Image

On the IQon Spectral CT, spectral reconstruction provides a single DICOM entity, known as the Spectral Base Image (SBI), that contains sufficient information for retrospective analysis. The SBI contains spectral results with no need for additional reconstruction or post-processing. Spectral applications create various spectral results from the SBI (Fig. 10).

IQon Spectral CT reconstruction

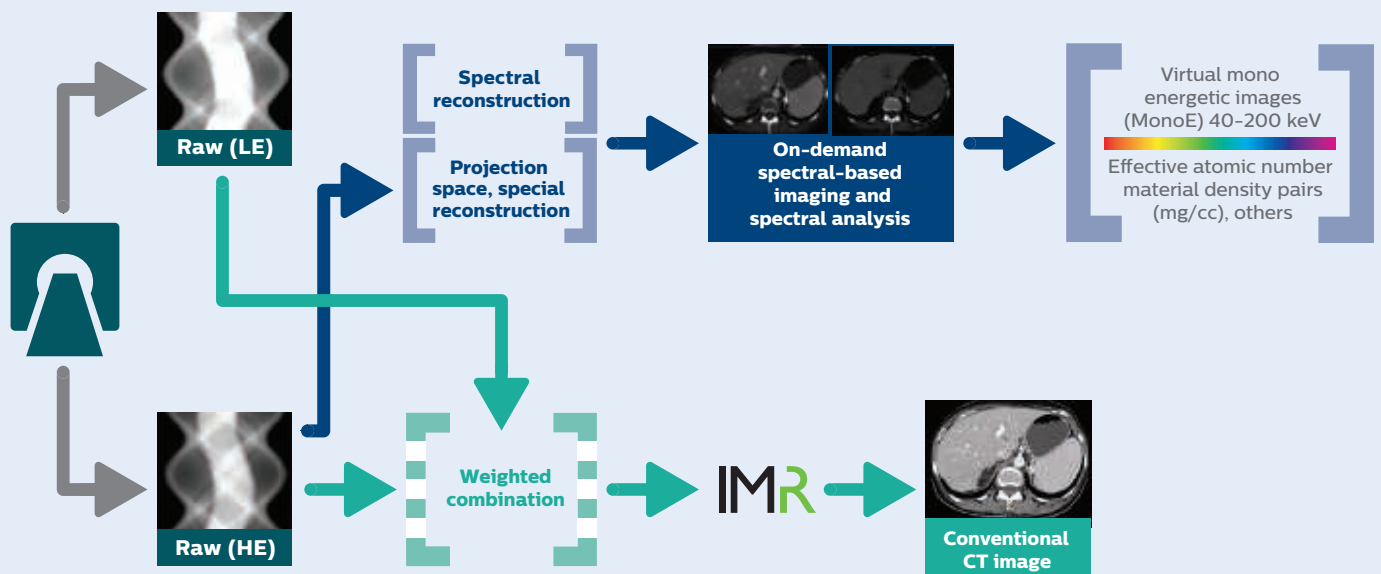


Fig. 10 Workflow that demonstrates how a single scan is used to generate both conventional and spectral results.

Obtaining spectral results with the IQon Spectral CT

Spectral results available on the IQon Spectral CT

Data contained within the SBI can be utilized into reconstructing several spectral results based on clinical needs and interventions. A summary of the various spectral results that can be obtained from the IQon Spectral CT are included in Table 3.

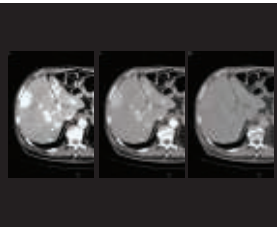
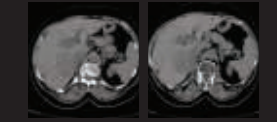



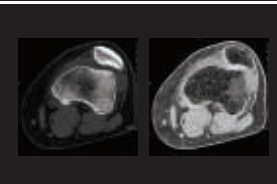
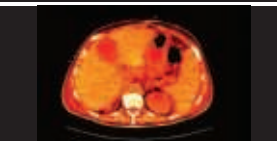
Example	Spectral Result	Description	Clinical Objective
	MonoE	Image that shows attenuation as if a single monochromatic energy (keV) were used to scan	<ul style="list-style-type: none"> • Boost of Iodine signal • Improvement in Contrast to Noise • Reduce beam hardening artifact • Metal artifact reduction
	Virtual Non Contrast	Shows image as if iodine component is removed	<ul style="list-style-type: none"> • Use when non-enhanced scans aren't performed • Dose management
	Iodine no Water	Material density images that allow iodine quantification	<ul style="list-style-type: none"> • Enhancement of iodinated contrast (Ca also bright) • Iodine isolation
	Iodine Density	Material density images that allow iodine quantification	<ul style="list-style-type: none"> • Enhancement of iodinated contrast (Ca removed) • Visualization & quantification of Iodine
	Z Effective	Effective Atomic Number (EAN)	<ul style="list-style-type: none"> • Ability to characterize structures based on material content
	Calcium Suppression	Image that shows HU values without calcium contribution to the attenuation	<ul style="list-style-type: none"> • Assessment of intervertebral disc herniation • Visualization of bone marrow involvement when bone fractures are present
	Electron Density	The values presented in the image are relative to the electron density of water (3.34×10^{29} electrons \times m^{-3}) in units of percent	<ul style="list-style-type: none"> • Estimate of electron density of each voxel

Table 3

Dose management tools available on the IQon Spectral CT

The detector-based approach of the IQon Spectral CT allows the user full access to all dose management tools, available in conventional scanning mode, at all times. Even when collecting spectral information, the IQon Spectral CT adheres to the Philips DoseWise approach, a set of techniques, programs and practices based on the ALARA principle to support outstanding image quality at low dose.

During scanning, tube current modulation is used to change the X-ray dose from location to location, attenuating the dose by body region. Image quality for each diagnostic task is specified by the DoseRight Index (DRI) for various scanning regions, to allow for the appropriate dose to maintain consistent image quality within a single acquisition.

- Personalized doses for individual patients are suggested by the DoseRight automatic current selection
- Longitudinal dose modulation is achieved using the DoseRight Z-DOM, which adjusts the tube current-time product (mAs) in the z-axis according to a patient's size and shape
- DoseRight 3D-DOM (three dimensional dose modulation) combines angular and longitudinal patient information to modulate dose in three dimensions (x-y-z-axis). It incorporates modulation of tube current-time product (mAs) according to changes in individual patient's size and shape in the transverse (x-y-axis; angular) direction during helical scans, in addition to changes in the craniocaudal or caudocranial (z-axis; longitudinal) direction, as the tube rotates
- Dedicated pediatric protocols offer high quality conventional images at low doses that take into account the pediatric patient's size and clinical indication

For conventional scans, Iterative Model Reconstruction (IMR) can generate images that are virtually noise-free. Besides improving on the quality of conventional imaging, studies using phantoms (data on file) suggest that IMR may reduce patient dose by 60–80% depending on the clinical task, patient size, anatomical location, and clinical practice.*

*In clinical practice, the use of IMR may reduce CT patient dose depending on the clinical task, patient size, anatomical location, and clinical practice. A consultation with a radiologist and a physicist should be made to determine the appropriate dose to obtain diagnostic image quality for the particular clinical task. Lower image noise, improved spatial resolution, improved low-contrast detectability, and/or dose reduction, were tested using reference body protocols. All metrics were tested on phantoms. Dose reduction assessments were performed using 0.8 mm slices, and tested on the MITA CT IQ Phantom (CCT183, The Phantom Laboratory), using human observers. Data on file.

Obtaining spectral results with the IQon Spectral CT

Phantom studies also suggest that Philips iDose⁴ improves spatial resolution and/or noise reduction at low dose. iDose⁴ is an innovative solution that helps clinicians personalize image quality based on patients' needs at low dose. When used in combination with the advanced scanner technologies, this provides a unique approach to managing important factors in patient care – low energy, low dose, and low injected contrast imaging.

Retrospective analysis and enhanced spectral visualization on the IQon Spectral CT

Using the IQon Spectral CT, the personalized quantitation of spectral CT data can be seamlessly integrated into established scanning and reading workflows. Since spectral data is retrospectively available with every scan on the IQon, there is no need to determine up front whether to scan a patient in spectral mode. If incidental abnormalities are encountered, there is no need to call the patient back for additional imaging. On-demand spectral results available for every patient scanned on the IQon allow the clinician to further inspect a region of interest in order to more closely evaluate the incidental finding.

After reviewing a conventional grayscale CT image, the clinician may decide that spectral information would be of additional value in a particular region of interest. In that case, spectral data acquired during a single scan can easily be accessed from the PACS for retrospective, on-demand, spectral data analysis.

Spectral CT Viewer

The Spectral CT Viewer is designed to enable spectral quantification through proprietary spectral tools. By offering unique capabilities across clinical areas, spectral applications provide additional anatomical and functional information to enhance diagnostic confidence.

Spectral Magic Glass

In addition to conventional CT images, Philips Spectral Magic Glass enables on-demand simultaneous viewing and quick comparison of up to five different spectral results for a region of interest, including monoenergetic, iodine density, virtual non-contrast, iodine no water and Z effective maps. The Spectral Magic Glass tool is superimposed on CT images to provide a color view of an area of special interest. Materials such as iodine, calcium, water, or fat can then be visually distinguished.

Spectral Magic Glass on PACS

The Spectral Magic Glass on PACS application conveniently launches directly in the user's PACS viewing setup, offering a simple interface that integrates into hospital workflow with little or no training required.

Clinical experience with IQon Spectral CT

Using the IQon Spectral CT clinicians have been able to:

- Generate high quality spectral images with no dose penalties
- Decrease beam hardening artifacts in scans, including those with metal implants
- Eliminate the patient selection dilemma by obtaining spectral results 100% of the time

Over 50 peer reviewed research publications support the effectiveness of the IQon Spectral CT. In these studies, spectral results from the IQon have demonstrated:

- Improved diagnostic confidence in CT scans by providing both anatomical and compositional information
- Workflow benefits, with always on spectral, that have reduced the need for repeat imaging scans
- Powerful advancements that reduce the need for follow up studies, making the first exam the right exam

Clinical experience with IQon Spectral CT

Increased diagnostic confidence through improved tissue visualization and characterization

Diagnostic challenge:

Unenhanced computed tomography of the head is a standard examination in conventional imaging of intracranial pathologies, such as ischemia or intracranial hemorrhage.^{24,25,26} Often, however, the efficacy of the image is limited by low signal-to-noise ratios and low contrast. Additionally, artifacts, mainly caused by the skull, add to the difficulties in making a conclusive clinical diagnosis from CT scans in such cases.^{27,28,29}

Overview and methods:

Forty patients, who received unenhanced CT scans on the IQon Spectral CT, were included in a study conducted by University Hospital in Cologne, Germany.³⁰ All patients were evaluated for suspected bleeding or ischemia and received scans with the same CT parameters. Polyenergetic and virtual monoenergetic images were reconstructed from the same scan. VNC images were reconstructed at 40 keV and 120 keV with 5 keV increments, using a proprietary Philips algorithm available on the IQon.

Representative images in the axial plane showing the basal ganglia and posterior fossa (width 75 HU; center 35 HU) were reviewed by two observers experienced in interpretation of head CT. The location and size of the regions of interest (ROIs) were kept constant in the polyenergetic and virtual monoenergetic images across keV levels. Image noise was considered to be represented by standard deviation in Hounsfield units for each ROI. The posterior fossa artifact index was measured. In addition, to quantify the beam hardening effect near the calvarium, the SD of an ROI near the calvarium served as a reference, subcalvarial artifact index (SAI). The signal-to-noise ratio (SNR) and the contrast-to-noise ratio (CNR) were also measured and analyzed between adjacent ROIs. For subjective measurement of image quality, the radiologist reading the scans rated the assessment of gray-white matter differentiation and of the subcalvarial, as well as artifacts caused by the skull and image noise using a five-point Likert scale.

Results:

When compared to conventional images:

- Virtual monoenergetic images at low keV levels had superior SNR and superior CNR of gray and white matter
- Subcalvarial artifacts were significantly lower at 120 keV
- Virtual monoenergetic images were rated superior in all four categories assessed
 - Gray-white matter assessment
 - Subcalvarial space assessment
 - Artifacts
 - Noise

Virtual monoenergetic images reconstructed from spectral scans improve image quality when compared to polyenergetic images, and allow for optimized grey-white matter contrast and reduced beam hardening artifacts.³⁰

Clinical experience with IQon Spectral CT

High quality spectral images with no dose penalties

Diagnostic challenge:

Image quality of true conventional images, routinely used for diagnostic purposes, are sacrificed with source-based spectral CT systems.

Overview and methods:

In a two-part study, Hojjati et al. looked at phantom and clinical data from two different University Hospitals to evaluate the image quality of conventional CT images from the Philips IQon Spectral CT compared to conventional images from a polyenergetic detector-based system (Philips iCT).³¹ ACR guideline-based phantom evaluations were performed on both systems for adult body protocol. Retrospective analysis was performed on 27 abdominal CT scans from each scanner. Scans included routine abdomen, as well as abdomen CTAs. Identical Regions of Interest (ROI) were reviewed at multiple locations in the abdomen, and attenuation, noise, SNR, and CNR values were measured. Subjective image quality analysis on a five-point Likert scale was looked at for enhancement, noise, and image quality. The Dose Length Product (DLP) reported by the scanner was recorded for all abdomen scans for both iCT and IQon CT systems.

Results:

- On phantom studies, the IQon Spectral CT- generated images met the ACR 34 requirements for CT number and deviation
- In patients:
 - Image quality scores were significantly higher for the IQon than the iCT, including enhancement, noise, and quality (Table 4)
 - The SNR in images was higher in the IQon than the iCT for liver, kidney, pancreas, and aorta (Table 5)
 - The CNR in images was higher for all abdominal organs in the IQon when compared to the iCT
- In abdomen scans, there were no significant differences in the mean DLP value for the IQon Spectral CT when compared to the iCT.

CT abdomen-all scans			
	IQon	iCT	<i>p</i>
Enhancement	4.78±0.38	4.50±0.56	0.006
Noise	4.64±0.36	4.30±0.45	0.000
Overall image quality	4.89±0.27	4.46±0.57	0.000

Table 4 Qualitative image scores in different protocols

CT abdomen-all scans			
	IQon	iCT	<i>p</i>
Liver	7.4±4.2	7.2±5.3	0.662
Spleen	8.6±4.1	7.4±3.5	0.152
Right kidney	11.1±6.3	8.7±5.0	0.033
Pancreas	6.90±3.45	6.11±2.64	0.303
Aorta	14.2±6.2	11.0±4.9	0.007
Bone	7.7±4.2	7.8±4.5	0.937

Table 5 SNR in different abdominal CT protocols

Spectral results generated on the IQon Spectral CT are generated without a loss in image quality of the standard conventional image, and without an increase in dose.³¹

Clinical experience with IQon Spectral CT

High quality spectral results from a single scan

Diagnostic challenge:

Accurate characterization of many incidentalomas, such as adrenal masses and hyperdense renal lesions, is contingent on their attenuation at unenhanced CT.^{32,33,34} In such instances patients are subjected to two scans and exposure to two times the dose, while images are subject to movement artifact.

Overview and methods:

In a HIPAA-compliant, IRB-approved prospective multi-institutional study, conducted by Anathakrishnan et al., 46 patients underwent pre- and post-contrast imaging on the IQon Spectral CT, yielding 84 unenhanced and VNC pairs (25 arterial, 39 portal venous/nephrographic, 20 urographic).³⁵ The mean attenuation was measured in the liver, spleen, kidneys, psoas muscle, abdominal aorta, and subcutaneous fat. Equivalence testing was used to determine if differences between unenhanced and VNC attenuation existed. VNC image quality was also assessed.

Results:

- VNC images derived from novel dual-layer spectral detector CT demonstrate attenuation values similar to unenhanced images in all tissues evaluated except for subcutaneous fat
- VNC image quality was rated as excellent or good in 84% of arterial phase and 85% of nephrographic phase cases (Table 6)

Position	Less than 15 HU
Liver	235/252 (93.3%)
Renal Cortex	153/159 (96.2%)
Spleen	79/84 (94.1%)
Aorta	73/82 (89.0%)
R psoas	77/82 (93.9%)
Fat SQ	69/82 (84.2%)
Total	686/741 (92.6%)

Table 6 Mean difference between unenhanced and VNC attenuation was <15 HU in 92.6%, <10 HU in 75.2%, and <5 HU in 44.4% of all measurements

Virtual non-contrast (VNC) images derived from contrast enhanced images acquired on the IQon Spectral CT demonstrate attenuation values similar to those created by unenhanced images, with acceptable image quality. This potentially eliminates the need for additional unenhanced scans, which would result in substantial radiation dose savings to the patient and elimination of movement artifact.³⁵

Clinical experience with IQon Spectral CT

Powerful advancements—decrease artifacts and enhance image quality

Diagnostic challenge:

Computed tomography is the imaging modality of choice in assessment of orthopedic implants.³⁶ However, assessment of metal implants, implant-bone interface and nearby structures is often impaired by artifacts.^{37,38} Artifacts can mask fracture or implant debris, surrounding hematoma and other pathological conditions, leading to misinterpretation of images.

Overview and methods:

In a study conducted by Hokamp et al., 28 consecutive patients with orthopedic hardware in the spine were scanned on the IQon Spectral CT. Conventional, O-MAR and monoenergetic (40–200 keV) images were reconstructed.³⁹

Attenuation (HU) and noise (SD) were measured in order to calculate signal-to-noise ratio (SNR) of paravertebral muscle and spinal canal. Subjective image quality was assessed by two radiologists in terms of image quality and extent of artifact reduction.

Results:

- O-MAR and high-keV monoenergetic images showed significant decrease of hypodense artifacts in terms of higher attenuation as compared to conventional (Table 7)
- Artifacts, depicted as noise, were found to be reduced in the paravertebral muscle and spinal canal in the O-MAR and high-keV monoenergetic images as compared to conventional images
- Subjectively, both O-MAR and high-keV images yielded an artifact reduction in up to 24/28 patients.

		Noise _{muscle}	CIN _{muscle}	Noise _{spinal canal}	CIN _{spinal canal}
	Conventional	34.7±19.0	68.6±60.0	103.4±61.3	91.2±63.4
	O-MAR	26.4±14.4	4.9±33.1	72.6±62.6	58.8±63.4
MonoE	40 keV	70.1±47.9	173.1±315.5	336.4±204.6	325.3±203.0
	105 keV	28.3±17.6	37.9±35.8	66.4±43.3	56.1±44.8
	140 keV	27.9±16.7	31.7±44.9	61.8±40.6	51.7±42.1
	200 keV	27.4±16.1	27.1±53.4	60.9±40.1	51.0±41.6

Table 7 Image noise [HU] and corrected image noise (CIN, [–]) for muscle and spinal canal at the patients front in conventional, O-MAR, and different MonoE levels (40, 105, 140, and 200 keV)^a

O-MAR and high-keV monoenergetic reconstructions provided on the IQon Spectral CT lead to objective and subjective artifact reduction in images.³⁹

Clinical experience with IQon Spectral CT

Diagnostic certainty—through multiple layers of spectral data, the first exam is the right exam

Diagnostic challenge:

Cervical and cerebral computed tomography angiography is a standard method for the evaluation of vessel stenosis and in the diagnosis of acute stroke,^{40,41} allowing the detection of vessel-occluding thrombi, atherosclerotic plaques or vascular malformations. However, polyenergetic CT images do not provide sufficient soft tissue and iodine contrast,^{42,43,44} especially near bone and within small arterial branches.

Overview and methods:

In a retrospective study, 30 patients who received a CT of the head and neck on an IQon Spectral CT were identified, and the polyenergetic as well as virtual monoenergetic images (40 to 120 keV) were reconstructed by Neuhaus et al.⁴⁵ Signals (\pm SD) of the cervical and cerebral vessels, as well as lateral pterygoid muscle and the air surrounding the head, were measured to calculate the CNR and SNR. In addition, subjective image quality was assessed using a five-point Likert scale.

Results:

- Objective and subjective analysis concluded virtual monoenergetic images had superior image quality compared to polyenergetic images in all evaluated categories (Table 8)
- Superior CNR and improved SNR in virtual monoenergetic images at 40 keV were found for all investigated vessels [internal carotid artery (C1 and C4 segments), vertebral artery, anterior cerebral artery, middle cerebral artery and posterior cerebral artery] with one exception – the SNR of the basilar artery was highest at 120 keV

Image quality index	PI	VMI	keV
Contrast	3 (2–4)*	5 (4–5)*	45 keV
Image Noise	3 (2–4)*	4 (3–5)*	120 keV
Arteries close to skull base	3 (2–4)*	5 (4–5)*	45 keV
Small arteries	3 (2–4)*	5 (4–5)*	45 keV

Table 8 Comparison of subjective image quality rated in polyenergetic and virtual monoenergetic images. p value was less than 0.0001 for all conditions.

PI, polyenergetic images; VMI, virtual monoenergetic images; *Arteries close to skull base*, assessment of arteries close to skull base; *small arteries*, assessment of small arteries (A2, M2, and P2 segments); *median + range

Virtual monoenergetic images reconstructed on the IQon Spectral CT at low keV ranging from 40 to 45 keV improve the objective and subjective image quality of extra- and intracranial vessels, and facilitate assessment of vessels close to the skull base and of small arterial branches.⁴⁵

Clinical experience with IQon Spectral CT

Diagnostic confidence at low contrast dose levels

Diagnostic challenge:

The increasing use of contrast media for diagnostic imaging purposes has made contrast induced acute kidney injuries the third most common cause of hospital-acquired AKI.^{46,47}

Overview and methods:

Fifty-one pediatric patients received contrast-enhanced CT simulation for radiation therapy on the IQon Spectral CT, a single source, dual-layer detector spectral CT during a study conducted by Tsang et al.⁴⁸ The contrast-to-noise ratios (CNRs) of blood vessels were measured relative to surrounding soft tissue. CNRs on monoenergetic 40–70 keV images were compared with polychromatic 120 kVp images. To compare with in vivo results, a phantom with iodine inserts (2–20 mg ml⁻¹ concentration) was scanned and CNRs were calculated relative to water background.

Results:

- Monoenergetic keV and body site had significant effects on CNR ratio ($p < 0.0001$). Across all body sites, the mean CNR (monoenergetic/polychromatic CNR) was 3.3
- Image noise was highest at 40 keV and lowest at 70 keV
- Phantom measurements indicated that the same CNR as 120 kVp images can be achieved with a 4.0-fold lower iodine concentration on 40 keV images and 2.5-fold lower on 50 keV images
- 50 keV monoenergetic images provided the best balance of improved CNR on all studies (mean 2.4-fold increase in vivo) for enhancing vessels vs image noise
- A 50% reduction in contrast dose on a 50 keV image should maintain comparable or better CNR as compared with polychromatic CT in over 80% of CT studies.

Use of a novel, single-source, dual-layer detector spectral CT scanner to improve visualization of contrast-enhanced blood vessels will reduce the amount of iodinated contrast required for diagnosis.⁴⁸

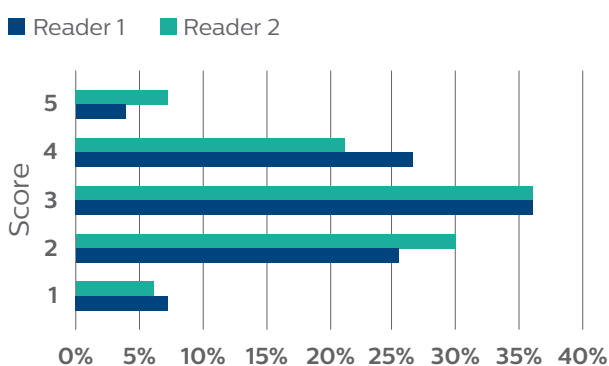
Spectral results 100% of the time, eliminating the patient selection dilemma

Diagnostic challenge:

Occasionally, unexpected findings on conventional CT scans require spectral results to improve diagnostic confidence. With traditional source-based spectral imaging, patients would require a second scan to gain these insights.

Overview and methods:

In a retrospective study conducted by Rajiah et al., 118 patients were scanned using the IQon Spectral CT. The benefit and clinical significance of retrospective spectral imaging in achieving a diagnosis was evaluated. Two radiologists were presented with a hypothetical challenge and were asked if they would have opted for a dual-energy scan, based on the clinical indication for a given patient, if only prospective selection for spectral data was available. They also reviewed the scans and documented the use of spectral data tools for clinical utility and significance on a five-point scale. Scores of 4 and 5 were considered to be clinically significant, i.e. they made an impact on the final diagnosis. For example, salvaging of sub-optimal vascular study by contrast enhancement or identification of incidental lesions was scored a 5. Lesion detection improvement by vascular contrast enhancement was given a score of 4. Decrease in artifacts that made underlying abnormality better was a 3. Artifact reduction was scored a 2 or a 1 depending on whether the change was minimal, but made no clinical impact.



Results:

- Spectral data would have been selected in 20 cases (17%) for Reader 1 and 25 (21%) cases for Reader 2. Additional spectral data was requested in 94 cases (80%) and 96 (81%) of cases respectively
- A total of 196 and 206 spectral image sets were utilized by each reader, with 97% and 96% deemed useful retrospectively

Fig. 11 Scores measuring the benefit and clinical significance of retrospective spectral analysis. Scores of 5 or 4 impacted the final clinical diagnosis. A scores of 3 demonstrated improved visualization of underlying abnormalities but did not change diagnosis. Scores of 2 or 1 reduced image artifacts.

Detector-based spectral imaging provides always-on and retrospectively available spectral data, offering clinicians a clinical advantage in cases where its not obvious that spectral results will be needed prior to scanning the patient.⁴⁹ Retrospective CT data reconstructed from the IQon Spectral CT improves the diagnostic capabilities by eliminating artifacts, improving contrast in vascular structures, and assisting in lesion characterization.

Clinical experience with IQon Spectral CT

Improve patient care and realize long-term economic benefits

Diagnostic challenge:

The costs associated with follow-up testing represent an opportunity cost in time, money, and patient comfort. Narrowing the diagnosis with the first test will ensure fewer follow-up tests before the onset of treatment, and ultimately improve patient outcomes.^{5,7}


Overview and methods:

Sixty patients were included in a study conducted by Norwood et al. to evaluate the long-term economic benefit of detector-based spectral CT.⁵⁰ These patients were divided into two groups. Group 1 consisted of 30 patients with reduced renal function (based on eGFR values) scanned without contrast on the Philips iCT. Patients were scanned with a collimation of 128*0.625 mm, slice thickness of 3 mm, slice increment of 3 mm, pitch of 0.984, at 120 kVp. Group 2 consisted of patients with reduced renal function scanned with 50–80 cc of contrast scanned on the IQon Spectral CT. Scanning protocol for patients in Group 2 was the same as Group 1. Both groups had CT scans that were obtained for head and neck; or chest, abdomen, and pelvis; or head and neck combined with chest, abdomen, and pelvis. Most of these patients were scanned for an oncology evaluation.

A retrospective data review on PACS and electronic management of records (EMR) was also performed to evaluate the number of follow-up scans received by patients in Group 1 and Group 2 over a period of three months following the initial non-contrast CT or low-contrast volume CT. EMR and PACs records were reviewed for every patient to collect information on the follow-up scans received on other imaging modalities, such as magnetic resonance imaging (MRI) and ultrasound. The dates of the original and follow-up scans on other modalities were recorded to calculate the time to final diagnosis. Time to diagnosis was calculated using the dates of the original CT exam and the follow-up exams.

Results:

- Use of contrast-enhanced scans on the IQon Spectral CT reduced the time to diagnosis of those patients from 100 days to 66 days: a 34% reduction in time to diagnosis.
- The 30 patients that received a non-contrast CT would need additional diagnostic tests. They would need an additional follow-up MRI and two ultrasound scans within a period of three months.
- This would result in additional average cost of \$453 per follow-up scan (based on the average cost of MRI = \$1109.43 and ultrasound = \$124.89, from Medicare reimbursement costs) in patients using non-contrast CT as compared to IQon in this group of patients.



25%

Reduction in
follow-up exams



34%

Reduction in
time to diagnosis



Savings of
\$453
per follow-up scan

Spectral CT reduces time and costs of patient diagnosis by decreasing the number of patient findings that are indeterminate.⁵⁰

PHILIPS

IQon Spectral CT



Summary

Spectral computed tomography is a diagnostic imaging technology that provides clinicians with anatomical and tissue composition details to help improve diagnostic confidence and accuracy. Diagnostic confidence and accuracy are essential to improve patient care while remaining competitive in the challenging health care business environment. By basing diagnoses on both anatomical as well as tissue characteristics, clinicians are able to more conclusively detect and characterize tumors, assess the hemodynamic significance of pulmonary embolisms, and characterize renal calculi, among several other conditions.

Of the several approaches to spectral CT imaging, the IQon's detector-based spectral technology provides advantages over source-based methods. Only a detector-based approach allows the clinician to adhere to the familiar conventional workflow, while retaining the full use of dose management tools and no compromise in the imaging field of view.

Detector-based spectral imaging:

- Bolsters diagnostic confidence
- Facilitates powerful imaging advancements
- Supports workflow advantages

Clinical studies involving oncology, cardiology, neurology, orthopedic, and pediatric patient populations have demonstrated the aforementioned advantages of the detector-based approach over alternatives. In all these studies, the detector-based approach demonstrated excellent patient and organization benefits. High quality spectral images, with no dose penalties, from a single scan, enables fast diagnosis, early onset of treatment, and long-term economic benefits – allowing a detector-based spectral approach to be a beneficial choice in routine CT imaging.

Works Cited

1. Holmboe, Eric S., and Steven J. Durning.
“Assessing Clinical Reasoning: Moving from in Vitro to in Vivo.”
Diagnosis, vol. 1, no. 1, Jan. 2014, pp. 111–117., doi:10.1515/dx-2013-0029.
2. Holmboe, Eric S., et al.
“Assessing Quality of Care: Knowledge Matters.”
JAMA, vol. 299, no. 3, 2008, pp. 338–340.
3. Pandharipande, Pari V., et al.
“Changes in Physician Decision Making after CT: A Prospective Multicenter Study in Primary Care Settings.”
Radiology, vol. 281, no. 3, 2016, pp. 835–846., doi:10.1148/radiol.2016152887.
4. Pandharipande, Pari V., et al.
“CT in the Emergency Department: A Real-Time Study of Changes in Physician Decision Making.”
Radiology, vol. 278, no. 3, 2016, pp. 812–821., doi:10.1148/radiol.2015150473.
5. Kassirer, J. P.
“Our Stubborn Quest for Diagnostic Certainty.”
New England Journal of Medicine, vol. 320, no. 22, 1989, pp. 1489–1491., doi:10.1056/nejm198911023211820.
6. Zhi, Ming, et al. “The Landscape of Inappropriate Laboratory Testing: A 15-Year Meta-Analysis.”
PLoS ONE, vol. 8, no. 11, 2013, doi:10.1371/journal.pone.0078962.
7. Welch, H. Gilbert.
Less Medicine, More Health: 7 Assumptions That Drive Too Much Medical Care.
Beacon Press, 2015.
8. Frush, D. P., et al.
“Computed Tomography and Radiation Risks: What Pediatric Health Care Providers Should Know.”
Pediatrics, vol. 112, no. 4, Jan. 2003, pp. 951–957., doi:10.1542/peds.112.4.951.
9. Kalra, Mannudeep K., et al.
“Strategies for CT Radiation Dose Optimization.”
Radiology, vol. 230, no. 3, 2004, pp. 619–628., doi:10.1148/radiol.2303021726.
10. Jessen K.A., et al.
“EUR 16262: European Guidelines on Quality Criteria for Computed Tomography.”
Luxembourg: Office for Official Publications of the European Communities, 2000.
11. Huda, Walter, et al.
“How Do Radiographic Techniques Affect Image Quality and Patient Doses in CT?”
Seminars in Ultrasound, CT and MRI, vol. 23, no. 5, 2002, pp. 411–422., doi:10.1016/s0887-2171(02)90012-0.
12. Radon, Johann.
“Über Die Bestimmung Von Funktionen Durch Ihre Integralwerte Längs Gewisser Mannigfaltigkeiten.”
Computed Tomography Proceedings of Symposia in Applied Mathematics, 1983, pp. 71–86.,
doi:10.1090/psapm/027/692055.
13. Alvarez, R. E., and A. Macovski.
“Energy-Selective Reconstructions in X-Ray Computerised Tomography.”
Physics in Medicine and Biology, vol. 21, no. 5, Jan. 1976, pp. 733–744., doi:10.1088/0031-9155/21/5/002.
14. X-Ray Absorption Edges, Characteristic X-Ray Lines... 4.2.1,
www.kayelab.npl.co.uk/atomic_and_nuclear_physics/4_2/4_2_1.html.

15. Roessl, E., and R. Proksa. “K-Edge Imaging in x-Ray Computed Tomography Using Multi-Bin Photon Counting Detectors.” *Physics in Medicine and Biology*, vol. 52, no. 15, 2007, pp. 4679–4696., doi:10.1088/0031-9155/52/15/020.
16. Schlomka, J. P., et al. “Experimental Feasibility of Multi-Energy Photon-Counting K-Edge Imaging in Pre-Clinical Computed Tomography.” *Physics in Medicine and Biology*, vol. 53, no. 15, Aug. 2008, pp. 4031–4047., doi:10.1088/0031-9155/53/15/002.
17. Schültke, Elisabeth, et al. “Synchrotron-Based Intra-Venous K-Edge Digital Subtraction Angiography in a Pig Model: A Feasibility Study.” *European Journal of Radiology*, vol. 73, no. 3, 2010, pp. 677–681., doi:10.1016/j.ejrad.2009.01.019.
18. Kijewski, M. F., and P. F. Judy. “The Noise Power Spectrum of CT Images.” *Physics in Medicine & Biology*, vol. 32, no. 5, 1987, doi:doi.org/10.1088/0031-9155/32/5/003.
19. Cunningham, I. A., et al. “A Spatial-Frequency Dependent Quantum Accounting Diagram and Detective Quantum Efficiency Model of Signal and Noise Propagation in Cascaded Imaging Systems.” *Medical Physics*, vol. 21, no. 3, 1994, pp. 417–427., doi:10.1118/1.597401.
20. Tapiovaara, M. J., and R. F. Wagner. “SNR and DQE Analysis of Broad Spectrum x-Ray Imaging.” *Physics in Medicine and Biology*, vol. 31, no. 2, Jan. 1986, pp. 195–195., doi:10.1088/0031-9155/31/2/510.
21. Wang, G., and M. W. Vannier. “Helical CT Image Noise-Analytical Results.” *Medical Physics*, vol. 20, no. 6, 1993, pp. 1635–1640., doi:10.1118/1.596950.
22. Brown Kevin M., et al. “Impact of Spectral Separation in Dual-Energy CT with Anti-Correlated Statistical Reconstruction.” *Proceedings of the 13th International Meeting on Fully Three-Dimensional Image Reconstruction*, 2015, pp. 493-496.
23. Sellerer, Thorsten, et al. “Dual-Energy CT: a Phantom Comparison of Different Platforms for Abdominal Imaging.” *European Radiology*, May 2018, doi:10.1007/s00330-017-5238-5.
24. Farzad, Ali, et al. “Emergency Diagnosis of Subarachnoid Hemorrhage: An Evidence-Based Debate.” *The Journal of Emergency Medicine*, vol. 44, no. 5, 2013, pp. 1045–1053., doi:10.1016/j.jemermed.2012.10.001.
25. Chalela, Julio A, et al. “Magnetic Resonance Imaging and Computed Tomography in Emergency Assessment of Patients with Suspected Acute Stroke: a Prospective Comparison.” *The Lancet*, vol. 369, no. 9558, 2007, pp. 293–298., doi:10.1016/s0140-6736(07)60151-2.
26. Hemphill, J. Claude, et al. “Guidelines for the Management of Spontaneous Intracerebral Hemorrhage.” *Stroke*, vol. 46, no. 7, 2015, pp. 2032–2060., doi:10.1161/str.0000000000000069.
27. Brooks, R. A., and G. Di Chiro. “Beam Hardening in x-Ray Reconstructive Tomography.” *Physics in Medicine & Biology*, vol. 21, no. 3, May 1976, pp. 390–398.

Works Cited

28. Young, S W, et al.
“Computed Tomography: Beam Hardening and Environmental Density Artifact.”
Radiology, vol. 148, no. 1, 1983, pp. 279–283., doi:10.1148/radiology.148.1.6856849.
29. Joseph, Peter M., and Robin D. Spital.
“The Effects of Scatter in x-Ray Computed Tomography.”
Medical Physics, vol. 9, no. 4, 1982, pp. 464–472., doi:10.1118/1.595111.
30. Neuhaus, Victor, et al.
“Improvement of Image Quality in Unenhanced Dual-Layer CT of the Head Using Virtual Monoenergetic Images Compared With Polyenergetic Single-Energy CT.”
Investigative Radiology, vol. 52, no. 8, 2017, pp. 470–476., doi:10.1097/rli.0000000000000367.
31. Hojjati, Mojgan, et al.
“Quality of Routine Diagnostic Abdominal Images Generated from a Novel Detector-Based Spectral CT Scanner: a Technical Report on a Phantom and Clinical Study.”
Abdominal Radiology, vol. 42, no. 11, Oct. 2017, pp. 2752–2759., doi:10.1007/s00261-017-1170-z.
32. Botsikas, Diomidis, et al.
“Incidental Adrenal Lesions Detected on Enhanced Abdominal Dual-Energy CT: Can the Diagnostic Workup Be Shortened by the Implementation of Virtual Unenhanced Images?”
European Journal of Radiology, vol. 83, no. 10, 2014, pp. 1746–1751., doi:10.1016/j.ejrad.2014.06.017.
33. Berland, Lincoln L., et al.
“Managing Incidental Findings on Abdominal CT: White Paper of the ACR Incidental Findings Committee.”
Journal of the American College of Radiology, vol. 7, no. 10, 2010, pp. 754–773., doi:10.1016/j.jacr.2010.06.013.
34. Choyke, Peter L.
“ACR Appropriateness Criteria® on Incidentally Discovered Adrenal Mass.”
Journal of the American College of Radiology, vol. 3, no. 7, 2006, pp. 498–504., doi:10.1016/j.jacr.2006.02.031.
35. Ananthakrishnan, Lakshmi, et al.
“Spectral Detector CT-Derived Virtual Non-Contrast Images: Comparison of Attenuation Values with Unenhanced CT.”
Abdominal Radiology, vol. 42, no. 3, 2017, pp. 702–709., doi:10.1007/s00261-016-1036-9.
36. Douglas-Akinwande, Annette C., et al.
“Multichannel CT: Evaluating the Spine in Postoperative Patients with Orthopedic Hardware.”
RadioGraphics, vol. 26, no. suppl_1, 2006, doi:10.1148/rg.26si065512.
37. Buckwalter, Kenneth A, et al.
“Multichannel CT Imaging of Orthopedic Hardware and Implants.”
Seminars in Musculoskeletal Radiology, vol. 10, no. 01, 2006, pp. 086–097., doi:10.1055/s-2006-934219.
38. Stradiotti, P., et al.
“Metal-Related Artifacts in Instrumented Spine. Techniques for Reducing Artifacts in CT and MRI: State of the Art.”
European Spine Journal, vol. 18, no. S1, 2009, pp. 102–108., doi:10.1007/s00586-009-0998-5.
39. Hokamp, Nils Große, et al.
“Reduction of Artifacts Caused by Orthopedic Hardware in the Spine in Spectral Detector CT Examinations Using Virtual Monoenergetic Image Reconstructions and Metal-Artifact-Reduction Algorithms.”
Skeletal Radiology, vol. 47, no. 2, 2017, pp. 195–201., doi:10.1007/s00256-017-2776-5.

40. Smith, Wade S., et al.
“Safety and Feasibility of a CT Protocol for Acute Stroke: Combined CT, CT Angiography, and CT Perfusion Imaging in 53 Consecutive Patients.”
American Journal of Neuroradiology, vol. 24, Apr. 2003, pp. 688–690.
41. Coutts, S. B., et al.
“ASPECTS on CTA Source Images Versus Unenhanced CT: Added Value in Predicting Final Infarct Extent and Clinical Outcome.”
Stroke, vol. 35, no. 11, 2004, pp. 2472–2476., doi:10.1161/01.str.0000145330.14928.2a.
42. Pomerantz, Stuart R., et al.
“Virtual Monochromatic Reconstruction of Dual-Energy Unenhanced Head CT at 65–75 KeV Maximizes Image Quality Compared with Conventional Polychromatic CT.”
Radiology, vol. 266, no. 1, 2013, pp. 318–325., doi:10.1148/radiol.12111604.
43. Neuhaus, Victor, et al.
“Improvement of Image Quality in Unenhanced Dual-Layer CT of the Head Using Virtual Monoenergetic Images Compared With Polyenergetic Single-Energy CT.”
Investigative Radiology, vol. 52, no. 8, 2017, pp. 470–476., doi:10.1097/rli.0000000000000367.
44. Sudarski, Sonja, et al.
“Optimization of KeV-Settings in Abdominal and Lower Extremity Dual-Source Dual-Energy CT Angiography Determined with Virtual Monoenergetic Imaging.”
European Journal of Radiology, vol. 82, no. 10, 2013, doi:10.1016/j.ejrad.2013.04.040.
45. Neuhaus, Victor, et al.
“Comparison of Virtual Monoenergetic and Polyenergetic Images Reconstructed from Dual-Layer Detector CT Angiography of the Head and Neck.”
European Radiology, vol. 28, no. 3, Oct. 2017, pp. 1102–1110., doi:10.1007/s00330-017-5081-8.
46. Rich, M. W.
“Incidence, Risk Factors, and Clinical Course of Acute Renal Insufficiency after Cardiac Catheterization in Patients 70 Years of Age or Older. A Prospective Study.”
Archives of Internal Medicine, vol. 150, no. 6, Jan. 1990, pp. 1237–1242., doi:10.1001/archinte.150.6.1237.
47. Nash, Kevin, et al.
“Hospital-Acquired Renal Insufficiency.”
American Journal of Kidney Diseases, vol. 39, no. 5, 2002, pp. 930–936., doi:10.1053/ajkd.2002.32766.
48. Tsang, Derek S, et al.
“Quantifying Potential Reduction in Contrast Dose with Monoenergetic Images Synthesized from Dual-Layer Detector Spectral CT.”
The British Journal of Radiology, vol. 90, no. 1078, 2017, p. 20170290., doi:10.1259/bjr.20170290.
49. Rajiah, Prabhakar, et al.
“Benefit and Clinical Significance of Retrospectively Obtained Spectral Data with a Novel Detector-Based Spectral Computed Tomography - Initial Experiences and Results.”
Clinical Imaging, vol. 49, 2018, pp. 65–72., doi:10.1016/j.clinimag.2017.10.019.
50. Norwood, Don, et al.
“Economic Impact of IQon for Patients with Renal Insufficiency.”
2017. Philips White Paper



© 2018 Koninklijke Philips N.V. All rights are reserved.

Philips reserves the right to make changes in specifications and/or to discontinue any product at any time without notice or obligation and will not be liable for any consequences resulting from the use of this publication.

Please visit [www.philips.com /iqon](http://www.philips.com/iqon)

Printed in The Netherlands.
4522 991 35951 * MAY 2018